

**PATIENT**

Jameson Yuan

**SPECIES**

Feline

**BREED**

DLH

**SEX**

Male Neutered

**AGE**

8 years

**WEIGHT**

12.75lbs

**INTERPRETED BY**

Maggie Machen  
Lamy, DVM, DACVIM  
(Cardiology)

**IMAGING PERFORMED BY**

Jenna Walsh, CVT

**HOSPITAL NAME**

Reid Veterinary  
Hospital

**REFERRING VET**

Dr. Reid/Yuan

**INVOICE**

29899

**DATE**

3/28/23

**PRESENTING CLINICAL SIGNS**

History: Heart murmur. Assess prior to dental.

**ELECTROCARDIOGRAPHIC FINDINGS** \*Note: Single lead ECGs are evaluated as a rhythm strip. Morphology/MEA cannot be definitively commented on.

A single lead ECG is available; 50mm/s, 20mm/mV. The average heart rate is 200bpm with a largely regular rhythm. P for every QRS complex and vice versa. The P and QRS morphologies are positive. No ectopic beats, pauses or dysrhythmias observed.

ECG diagnosis: Normal sinus tachycardia.

**ECHOCARDIOGRAM FINDINGS**

2D, m-mode, color flow and doppler imaging is available. The left ventricular wall is normal in dimension. There is a hyperechoic endocardium consistent with fibrosis. The left atrium is normal in size. Mild MV thickening with mild mitral regurgitation. No obvious systolic anterior motion of the MV is seen. The right atrium is normal in size. The right ventricle appears normal. Trace TR. Normal velocity (2.0m/s). Blood flow through both the LVOT and RVOT are normal in velocity. No AI or PI. No effusions or cardiac tumors are identified.

**CARDIAC CHART**

FELINE CARDIAC PARAMETERS	BODY WEIGHT (kg)	HR (BPM)	IVSd (cm) (Moise, Pipers)	LVIDd (cm) (Moise, Pipers)	LWVd (cm) (Moise, Pipers)	FS (%)	EF (%)
NORMAL PARAMETER	-----	150-240	0.35-0.55	<2 (mean 1.5)	3.5-0.55	35-67	80-100
PATIENT	5.8	190	0.45	1.7	0.45	58	90
FELINE CARDIAC PARAMETERS	LA/AO (Boon)	LA/AO HEART BASE (Swe) (Abbott)	LA 2D short axis Base view (cm) (Abbott)		LVOT VEL (m/s)	RVOT VEL (m/s)	E max (m/s)
NORMAL	<1.5	<1.3	<1.2		<1.6	<1.3	<0.9
PATIENT	1.3	1.2	1.2		1.3	1.0	NM

*\*Note: All measurements based upon multi-modal images and methods. An average value is reported.*  
 Adapted from June Boon, Veterinary Echocardiography, 1998  
 Abbott J & MacLean H JVIM 2006;20: 111-119, Moise et al. Am J Vet Res 47:1476, 1986. Pipers et al. Am J Vet Res 40:882, 1979.

**INTERPRETATION OF THE FINDINGS & FURTHER RECOMMENDATIONS**

The cause of the murmur is mild mitral and tricuspid regurgitation. MR in cats is typically due to either MV dysplasia (abnormal morphology from birth) or secondary to abnormal valve motion (SAM/HOCM), neither of which are seen in this study. Mild MV thickening may represent early valve disease similar to as seen in dogs, and serial monitoring is advised. The left atrium is normal, indicating the risk for associated clinical signs and CHF at this time however, and no medications are indicated. The ECG is unremarkable with a normal sinus rhythm.

Given a normal LA dimension, no medications are indicated and simple follow up is advised. Risk is low for complication; however, long-term prognosis is guarded given the highly variable rates of progression of sub-clinical feline cardiomyopathy.



**PATIENT**

Jameson Yuan

The risk for general anesthesia is low, however heart rate stimulating drugs such as atropine, glycopyrrolate should be avoided unless medically necessary. Even without significant pathology, there is a mildly elevated risk for fluid overload in this patient. Judicious IV fluid use is recommended.

**SPECIES**

Feline

Recheck echocardiogram is recommended in 6 months, sooner if development of any clinical signs.

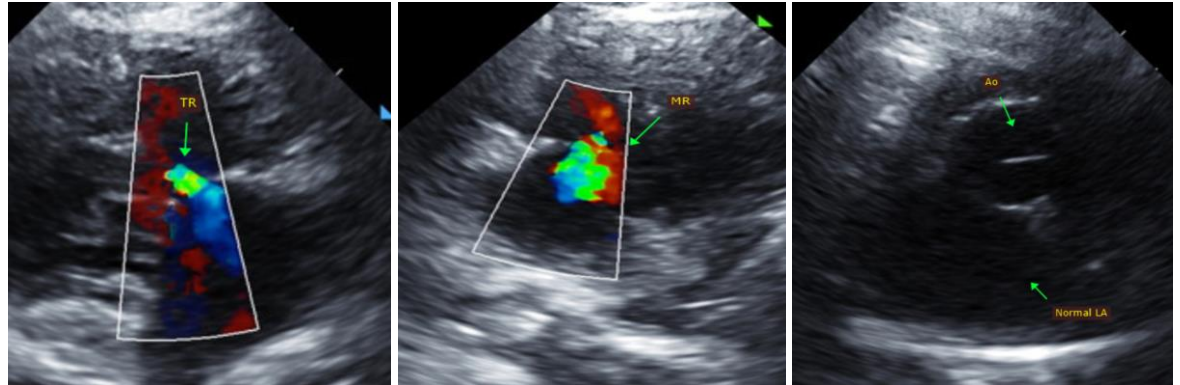
**BREED**

DLH

**IMAGES**

**SEX**

Male Neutered

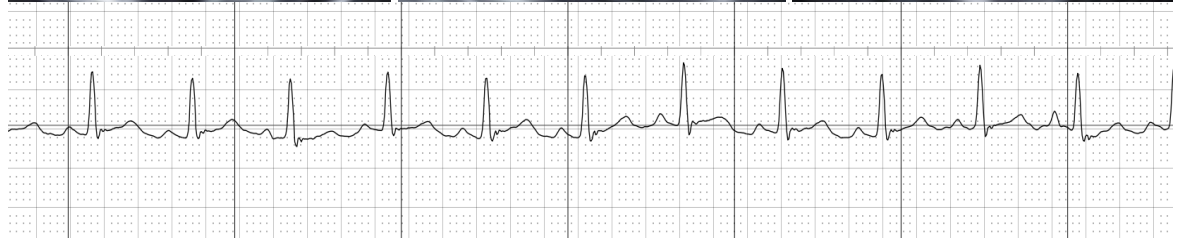

**AGE**

8 years

**WEIGHT**

12.75lbs



**INTERPRETED BY**

Maggie Machen Lamy, DVM, DACVIM (Cardiology)

The information and recommendations provided are based on the images presented by the referring veterinarian. No evaluation can be communicated regarding pathology that was not visible in the image/video clips provided.

**IMAGING PERFORMED BY**

Jenna Walsh, CVT

Thank you for this referral. This report was generated using transcription software, and minor dictation errors may be present. If the clinical or image interpretation does not parallel your findings or if I can be of any further assistance please contact me.

**HOSPITAL NAME**

Reid Veterinary Hospital

**Maggie Machen Lamy, DVM**  
Diplomate of the American College of Veterinary Internal Medicine (Cardiology)  
info@sonopath.com

**REFERRING VET**

Dr. Reid/Yuan

**INVOICE**

29899

**DATE**

3/28/23